

Omoigui S. Spinal Pain and Fluoroscopy Guided Facet Joint, Facet Medial Branch Nerve and Epidural Injections - A critical review of the science and the evidence. Proceedings of the L.A. Pain Clinic. Medicinehouse.com January 2009

## **Spinal Pain and Fluoroscopy Guided Facet Medial Branch Nerve and Epidural Injection – A critical review of the science and the evidence**

**Authors:** Sota Omoigui MD

**Affiliation:** Division of Inflammation and Pain Research

L.A. Pain Clinic, Los Angeles, California

**Publisher:** Medicinehouse.com

All authors have read and approved the manuscript. Work was done at the L.A. Pain Clinic. The study was not supported by any grant. There is no conflict of interest.

**ABSTRACT** – We review and analyze the science and the evidence in several opinions that are repeatedly found in pain and radiology literature. There is no evidence for a single pain trigger in the spine where inflammation is confined. Inflammation and the inflammatory process are characterized by recruitment and spread. There is evidence to revise the current focus on searching for one pain trigger at a time to acknowledging and targeting of multiple pain triggers responsible for spinal pain. There is no evidence that a block utilizing fluoroscopy for either medial branch or epidural blockade translates into a greater therapeutic advantage than a block performed utilizing anatomical landmarks. Fluoroscopy is required when anatomical landmarks are difficult to discern and with procedures that bring the needle close to vital structures. As a diagnostic tool, the facet intra-capsular injection is meaningless and this procedure should be discontinued. There is no scientific foundation and no evidence that fluoroscopic guidance can result in a limited, controlled or diagnostic block of the medial branch innervation to the facet joint. A medial branch block administered as a diagnostic test cannot localize the pain to the facet joint. In the absence of systemic analgesia, the block confirms that the source of pain is from any or several of the posterior spinal structures innervated by the medial branch nerve (facet joints, facet capsular ligaments, the interspinous and supraspinous ligaments, spinous process and paraspinal multifidus muscles). EMG guidance during a medial branch block - whether performed with fluoroscopic guidance or by utilizing anatomical landmarks - is the only objective method of confirming accuracy of the procedure. There are no studies that demonstrate increased safety or

efficacy of facet medial branch nerve blocks using fluoroscopy compared with the use of anatomical landmarks. The constant questioning of “established” truths is necessary for progress and improvement in outcome at optimum cost.

**Keywords:** Fluoroscopy; anatomical landmark; guidance; diagnostic; blind; facet intracapsular joint; facet nerve; medial branch; dorsal ramus; epidural

## **INTRODUCTION**

### **SPINAL PAIN AND MULTIPLE PAIN GENERATORS**

Spinal pain is the second most common reason for a visit to a doctor's office and the leading cause of disability in people younger than 45 years of age. Spinal pain may arise from arthritis of the facet or sacro-iliac joints, degenerative disk disease, herniated disks, nerve root compression, spinal stenosis, ligamentous or muscular strain/sprain, osteoporotic or osteolytic fractures, misalignment of the vertebra, tumors and infection. The common biochemical thread in these structural lesions is the presence of inflammation and the inflammatory response<sup>1</sup>. Non-spinal causes of back or neck pain include genitourinary, gynecologic, gastrointestinal, or systemic disease. In the majority of patients, the origin of back pain is not from a single pathology but rather multifactorial with the pain arising from a variety of structures (muscles, ligaments, facet joints, nerves, disks and bone)<sup>1</sup>. Discogenic disease with disc space narrowing progressively transfers more weight to the facet joints thereby damaging the joints. Mechanical stress that affects a joint will affect the surrounding tissue. Degenerative spinal

disorders that lead to facet osteoarthritis will also affect other structures in the spinal segment. For example, chronic arthritis of the posterior facet joints is usually associated with hypertrophy and degeneration of fibers of the ligamentum flavum<sup>2</sup> or with degenerative disk disease<sup>3</sup>. In females, the more frequent pathologies, in decreasing order, were: bulging disc, synovial facet syndrome, disc herniation and vacuum phenomenon. In males incidence and frequency of various pathologies were similar to that observed in females<sup>4</sup>.

In one study, volumetric CT imaging of the lumbo-sacral column was performed in 2012 consecutive patients with back pain, and included 866 males and 1,146 females, aged 22 to 91 years. 172 males were affected by one pathologic lesion, 586 from 2 to 4, 102 more than 4 lesions; 6 subjects were without. On the contrary, 196 females had a single lesion, 611 from 2 to 4, 331 more than 4 and 8 did not have any one. In another study, magnetic resonance and computed tomography scans of L4/5 and L5/S1 levels in 129 patients operated for herniated intervertebral disc were assessed to establish the relationship of facet joint asymmetry, disc prolapse and degenerative disease. Statistical analysis revealed significant correlation between facet joint asymmetry and disc disease or degenerative stenosis within lumbar spine<sup>5</sup>. Another study determined the relationship between facet joint osteoarthritis and disc degeneration in subjects in whom both MRI and CT scans had been obtained. Sixty-eight sets of scans were included and 330 discs and 390 facet joints were evaluated. There were 144 degenerated discs and 41 levels with facet osteoarthritis. Disc degeneration without facet osteoarthritis was found at 108 levels, while all but one of 41 levels

with facet degeneration also had disc degeneration. That one exception occurred in a patient with advanced Paget's disease. Disc degeneration and facet osteoarthritis both were found to increase with increasing age. The authors concluded that disc degeneration occurs before facet joint osteoarthritis, which may be secondary to mechanical changes in the loading of the facet joints<sup>3</sup>.

## TREATMENT OF SPINAL PAIN

Many medical specialties treat this highly prevalent condition and the type of intervention performed is highly variable and dependent on the specialty of the treating physician. Back or neck pain that does not respond to medical treatment by the primary care physician or surgical intervention by the orthopedic or neurosurgeon is often referred to the interventional pain specialist. Utilizing the history, clinical examination, imaging, electro-diagnostic and laboratory studies, the pain physician establishes the possible etiology of the spine pain. It should be noted that radiographic abnormalities demonstrating osteoarthrosis of the lumbar spine and facet joints and varying degrees of disk bulge and disk degeneration are the rule in both asymptomatic and symptomatic patients<sup>6</sup>. A high rate of lumbar disc alterations and spinal stenosis is also detected in asymptomatic individuals by magnetic resonance imaging<sup>7 8</sup>. Facet joint, medial branch nerve blocks and epidural steroid injections are most commonly performed interventions utilized frequently by the pain specialist for the treatment of chronic spinal pain. These diagnostic and therapeutic interventions are based upon numerous opinions and guidelines are stated in the pain and radiology literature.

Implementation of these opinions and guidelines are associated with a significant increase in medical costs. The costs of interventional treatment for spinal pain were at a minimum of \$13 billion (U.S. dollars) in 1990, and the costs are growing at least 7% per year. Medical treatment of chronic pain costs \$9000 to \$19,000 per person per year<sup>9</sup>. There is a need for a critical evaluation of the evidence behind these opinions and guidelines as most of these publications have not documented any outcome studies or cost-benefit analysis of some of the procedures that they advocate.

#### OPINIONS AND GUIDELINES IN THE LITERATURE

Numerous opinions and assertions are stated in the pain and radiology literature and repeated so often that they get a life of their own and become “established” truths. One of these is the statement that that diagnostic blocks of the facet joints or their nerve supply are the only means available to confirm or deny these structures as pain generators<sup>10 11</sup>. Other opinions hold that needle position is synonymous with success of a nerve block and needle position can only be accurately verified using fluoroscopy<sup>12 13</sup>. Another opinion often repeated is that imaging-guided techniques appear to provide better results and reduce complication rates<sup>12</sup>. This has led to other opinions in the pain and radiology literature<sup>14 15 16 11</sup>, which advocate that fluoroscopy, be required for performance of diagnostic and therapeutic facet medial branch nerve and epidural injections. We now set out to analyze the science and the evidence to justify the opinions and theories.

## **METHODOLOGY**

We first analyze the anatomical foundation for diagnostic and therapeutic facet medial branch nerve blocks and epidural injections. We review the recommendation of fluoroscopy for facet medial branch nerve blocks and epidural injections. We then analyze the medical literature that has been used to support these recommendations. The literature review was conducted by a database search of Medline (PubMed, Ovid and MDConsult) database published to December 2007. The keywords used in various combinations were fluoroscopy, pain, injection, facet joint, medial branch nerve, block, articular, adverse effect, complication and epidural injection. We identify and analyze the relevant literature that has been used to support these opinions and recommendations. Our analysis includes a selection of studies whose conclusions are based upon flawed study designs and a lack of scientific foundation. Where appropriate we highlight opinions and theories in the pain literature that have no scientific foundation and are not supported by any studies including but not limited to randomized controlled trials and controlled clinical trials.

## **RESULTS**

### **FLUOROSCOPY**

Fluoroscopy is a radiologic technique that uses x-ray to produce real-time video images. After the x-rays pass through the patient, instead of using film, they are

captured by a device called an image intensifier and converted into light. The light is then captured by a TV camera and displayed on a video monitor.

Fluoroscopy provides excellent visualization of bone structures, but soft tissue resolution is poor. When using fluoroscopy for interventional procedures the operator must rely upon secondary anatomical landmarks when targeting soft tissue structures unless contrast is used. Contrast material is needed to visualize tubular structures with fluoroscopy. One disadvantage of fluoroscopy is the definitive radiation exposure to the operator and the patient. The radiation dose varies according to fluoroscopy time, which is dependent upon the procedure

Fluoroscopy enables better structural accuracy of needle positioning over a bony landmark in order to block the nerve branches in close proximity. It ensures immediate discovery of a wrong needle position either away from the target or intravascular (when contrast is injected), before a local anesthetic or other substance is injected. Techniques for medial branch nerve blocks utilizing anatomical landmarks have been described in numerous articles and textbooks<sup>17 18 19</sup>. There are currently no studies that demonstrate increased safety, efficacy or outcome of facet medial branch nerve blocks or epidural injections using fluoroscopy compared with the use of anatomical landmarks. The principal rationale for the opinions advocating fluoroscopy for medial branch nerve blocks is that needle position is synonymous with success of a nerve block and needle position can only be accurately verified using fluoroscopy<sup>12 13</sup>. However, the medial branch nerve innervates several structures including the facet joints, facet capsular ligaments, the interspinous and supraspinous ligaments, spinous

process and paraspinal multifidus muscles. Thus relief of pain subsequent to blockade of the medial branch can be due to blockade of nociceptive afferent input from any combination of these spinal structures and/or blockade of nociceptive efferent input to the paraspinal musculature. Fluoroscopy cannot image or target the branches of the medial branch nerve that are involved in the inflammatory process and cannot visualize or target the inflammatory mediators generated by the posterior spinal structures. The medial branch nerves being blocked using fluoroscopic guidance or anatomical landmarks may or may not innervate the posterior spinal structures that are involved in inflammation and pain. Fluoroscopy is required when anatomical landmarks are difficult to discern and in the performance of procedures that bring the needle close to vital structures such as a celiac plexus block or with nerve destruction procedures such as radiofrequency lesioning. Fluoroscopy should also be utilized to ensure reliability and consistency of needle position when a medial branch block is performed as a diagnostic block prior to radiofrequency neurotomy. Fluoroscopic imaging is helpful with teaching and demonstrating injection techniques, providing a record of the procedure, advancing through a learning curve, providing a level of comfort of the practitioner thereby enhancing performance and providing reassurance that the block was performed adequately if a clinical failure arises. In his response to a Letter to the Editor criticizing the use of anatomical landmarks for medial branch blocks, Waldman stated that the use of fluoroscopic guidance should be based upon the clinician's individual training or experience and a careful weighing of the cost-benefit ratio and risk-benefit

analysis for the use of fluoroscopy<sup>14</sup>. Fluoroscopy is associated with significantly higher medical costs as well as exposure to radiation. In one study cost minimization analysis suggested that epidural injections under fluoroscopy may not be justified by the current literature<sup>9</sup>.

#### DECREASED COMPLICATION RATE WITH USE OF FLUOROSCOPY

Opinions have also been expressed in the radiology literature stating that despite controversy regarding their effectiveness, imaging-guided techniques appear to provide better results and reduce complication rates<sup>12</sup>. We did not find a single study that measured and documented a decrease in complication rate with the use of fluoroscopy. There is no study in the literature that has measured safety, efficacy or outcome with the use of fluoroscopic guidance compared with the use of anatomical landmarks in the performance of facet medial branch nerve blocks and epidural injections. Complications and adverse effects may occur with either the use of fluoroscopy or the use of anatomical landmarks to perform these procedures, as neither technique can visualize the nerves or the spinal cord<sup>20 21</sup>. The use of fluoroscopy has not provided any protection from liability suits over complications. In the last two decades in the United States, there has been increasing use of fluoroscopy in the performance of interventional pain procedures by anesthesiologists and radiologists including epidural injections. One study identified and described issues and trends in liability related to chronic pain management by anesthesiologists. Data from 5,475 claims in the American Society of Anesthesiologists Closed Claims Project database between 1970 and 1999 were reviewed to compare liability related to chronic pain management with

that related to surgical and obstetric (surgical/obstetric) anesthesia. Acute pain management claims were excluded from analysis. Claims related to chronic pain management increased over time ( $P < 0.01$ ) and accounted for 10% of all claims in the 1990s. Compensatory payment amounts were lower in chronic pain management claims than in surgical/obstetric anesthesia claims from 1970 to 1989 ( $P < 0.05$ ), but during the 1990s, there was no difference in size of payments. Nerve injury and pneumothorax were the most common outcomes in invasive pain management claims. Epidural steroid injections accounted for 40% of all chronic pain management claims. The authors concluded that frequency and payments of claims associated with chronic pain management by anesthesiologists increased in the 1990s<sup>22</sup>. Updated data from the ASA Closed Claims Project database ( $n=7,328$ ) was also used to compare chronic pain claims from 1985-94 to chronic pain claims from 1995-2004<sup>23</sup>. Just as previous trends have shown, chronic pain claims continued to increase from 7 percent (222 of 3,152 claims) in 1985-94 to 12 percent (224 of 1,839 claims) in 1995-2004 ( $p<0.01$ ). Neuraxial blocks and injections were the most common chronic pain intervention in claims, accounting for nearly half (47 percent) of the most recent chronic pain claims. Cervical blocks and injections increased from 5 percent of chronic pain claims in 1985-94 to 14 percent in 1995-2004 [ $p<0.01$ ]. Patterns of injury associated with chronic pain management malpractice claims have changed over time. The proportion of claims associated with nerve injury significantly increased between time periods and now accounts for the most common complication (38 percent) in chronic pain management claims. These

nerve injuries (n=86) included both peripheral nerve injury (n=43) and spinal cord injury (n=48) (five claims had both peripheral nerve and spinal cord injury).

Due to the risk of serious neurological injury following inadvertent intra-arterial injection of particulate corticosteroid - not detected by aspiration or vascular uptake of contrast<sup>24</sup> - , it is recommended to use only soluble corticosteroids such as Dexamethasone for transforaminal epidurals or selective nerve root blocks. Careful monitoring of local anesthetic dosing should be done to ensure that toxic levels are not attained even with accidental intravenous or epidural injections.

#### USE OF FLUOROSCOPY FOR EPIDURAL INJECTION

There is currently no consensus on the technical aspects of performing epidural injections with or without fluoroscopy. One study done at MGH set out to establish whether consensus exists on technical aspects of this procedure. The study found that there is a wide variation among individual practices in almost every technical aspect of epidural steroid injections. Private practices use significantly more fluoroscopy than academic centers. The authors concluded that there is no consensus on the use of fluoroscopy<sup>25</sup> A requirement for fluoroscopy for epidural injections makes no consideration of the mechanics, pathophysiology or inflammatory profile of spinal trauma or degenerative spinal disorders. A review of the numerous studies of the diffusion patterns of liquid local anesthetics will demonstrate that there is no linear correlation between needle position and success of a nerve block. One study demonstrated a lack of a linear relationship between injected volume of local anesthetic and spread of

epidural anesthesia<sup>26</sup>. Another study examined the site of catheter tips and the spread of contrast material in the epidural space using computed tomographic (CT) imaging in patients receiving successful epidural analgesia. Catheter tips were most often found lateral to the dura in the intervertebral foramen. In these subjects with normally functioning epidural analgesia, there was remarkable inter-individual variability in patterns of spread, including various amounts of anterior passage, layering along the dura, and compression of the dura creating a posterior fold. The author concluded that non-uniform distribution of injectate is common and is compatible with uniform anesthesia<sup>27</sup>.

#### DIAGNOSTIC USE OF NEURAL BLOCKADE

Intra-articular facet joint or medial branch nerve block is currently recommended for the diagnosis and treatment of painful conditions involving trauma, arthritis, or inflammation of the spinal facet joints or in situations where the facet joint is thought to be contributing to afferent nociceptive traffic<sup>28</sup>. Diagnostic blocks have been used to obtain information about the source of a patient's pain<sup>29</sup> and medial branch blocks are described as a diagnostic tool for facet joint pain<sup>30</sup>. Some opinions in the pain and radiology literature<sup>14 15 16</sup> and guidelines from societies such as the American Society for Interventional Pain Physicians (ASIPP)<sup>11</sup> have advocated the performance of diagnostic facet joint and facet medial branch nerve injections. However, these guidelines have been recently challenged, and a recent journal editorial of one of such societies stated: "A SHOCKING PROBLEM UNEARTHED: What if there is no such thing as a 'diagnostic' medial branch block or

for that matter, a 'diagnostic' nerve block?"<sup>31</sup>. Some of these opinions state that diagnostic blocks of the facet joints or their nerve supply are the only means available to confirm or deny these structures as pain generators<sup>10 11</sup>. However these opinions are based upon erroneous assumptions and severely flawed anatomical studies of the spread of contrast medium after injection of the medial branch nerves<sup>32</sup>. There has been no examination of the shared medial branch and sinu-vertebral innervation of the facet joints with other pain triggers in the posterior spinal structures. There has been no consideration of the mechanics, pathophysiology or inflammatory profile of spinal trauma or degenerative spinal disorders. They have not reviewed the numerous studies of perineural transport and spread of injectate in peripheral nerve blocks<sup>33 34</sup>. As stated in an article by Hildebrandt<sup>35</sup>, these opinions on the diagnostic use of neural blockade rests on three unsubstantiated premises. First, pathology causing pain is located in an exact peripheral location, and impulses from this site travel via a unique and consistent neural root. Second, injection of local anesthetic totally abolishes sensory function of the intended nerves and does not affect other nerves. Third, relief of pain after local anesthetic block is attributable solely to block of the target afferent neural pathway. Hildebrandt further stated that complexities of anatomy, physiology, and the psychology of pain perception and the effect of local anesthetics on impulse conduction limit the validity of these assumptions.

## ANATOMY OF THE FACET JOINT

The facet joint is made up of an inferior articular process from the vertebra above and a superior articular process from the next vertebra below (Fig. 1). There is a ligamentous capsule surrounding the joint, and a synovial membrane lining the inner aspects of the articular processes- similar to the anatomy of other joints.

Facet capsular ligaments have been shown to contain free (nociceptive) nerve endings, and distending these ligaments by administering facet joint injections has produced whiplash-like pain patterns in healthy individuals<sup>36</sup>. The facet capsule is richly innervated with C fibers and A-delta pain fibers<sup>3738</sup>. Local pressure and capsular stretch can mechanically activate these nerves. These neurons can be sensitized or excited by inflammatory mediators including cytokines, substance P and phospholipase A that are produced from injury to the capsule<sup>39</sup> or from adjacent tissues<sup>40</sup> (vertebrae, intervertebral discs, spinal cord, nerve roots, sensory nerves, the sympathetic nervous system, spinous process, interspinous and supraspinous ligaments, or muscles). Input of noxious stimuli from spinal trauma may induce physiologic changes in the spinal cord, particularly the dorsal horn.

#### NERVE SUPPLY OF THE FACET JOINT AND ADJACENT STRUCTURES

At the level of the intervertebral foramen is the dorsal root ganglion. The ganglion lies within the outer confines of the foramen. Distal to the ganglion three distinct branches arise; the most prominent and important is the ventral ramus, which supplies all structures ventral to the neural canal. The second branch, the sinuvertebral nerve of Luschka, is a small filamentous nerve that originates from the ventral ramus. The sinuvertebral nerve is formed just outside the intervertebral

foramen with contributions from the main segmental nerve and from the grey ramus communicans, whose cell bodies are located in the sympathetic trunk<sup>84</sup>. The sinuvertebral nerve progresses medially over the posterior aspect of the disc and vertebral bodies, innervating these structures as well as the posterior longitudinal ligament and the facet joint. The third branch is the dorsal ramus. This branch courses dorsally, piercing the intertransverse ligament near the pars interarticularis. Three branches from the dorsal ramus innervate the structures dorsal to the neural canal. The lateral and intermediate branches provide innervation to the posterior musculature (longissimus and iliocostalis muscles of the erector spinae apparatus) and skin. The medial branch separates into three branches to innervate the facet joint at that level and the adjacent levels above and below<sup>41 42</sup>. The medial branch continues across the lamina just deep to the multifidus muscle and sends a branch to the interspinalis muscle, and eventually enters the multifidus muscle. Terminal branches of the medial branch supply the ligaments and periosteum of the vertebral arches and spines<sup>43</sup>. The discs, vertebrae, intervertebral discs, muscles, facet joints and facet capsular ligaments and spinal ligaments at the same level are in close proximity to each other and share the same dorsal ramus nerve supply and may also share the nerve supply of an adjacent segment. The medial branches of the dorsal ramus do not constitute the only nerve supply to the facet joints. The facet joints are also innervated by the sinu-vertebral nerve, branches from the ventral ramus<sup>44</sup> and sensory nerves passing through the sympathetic trunk. Studies have demonstrated that the neuropeptide levels in the cell bodies located within the

dorsal root ganglion of these sensory nerves fluctuate according to the physiological state of the zygapophyseal joint<sup>45</sup>.

In one study in a cat, electrical stimulation of a lumbar facet capsule evoked lumbar multifidus muscle electromyographic activity. Injection of lidocaine into the facet or into the multifidus muscle around the facet joint significantly decreased the magnitude of the multifidus electromyography one to two vertebral segments caudal to the stimulated facet. These findings indicate that afferent pain impulses conveyed by the medial branch of the dorsal ramus reflexly alter efferent activity to an adjacent lumbar muscle segment<sup>46</sup> Another study determined whether the lumbar multifidus muscle is polysegmentally innervated by the medial branch nerve. A 49-year-old man with chronic mechanical low back pain underwent bilateral percutaneous radiofrequency neurotomy of the medial branches of the L3 dorsal rami. Electromyography (EMG) examination was performed in the L2-5 multifidi both prior to and 3 weeks after the procedure. Positive sharp waves and fibrillations appeared in the L3-L5 multifidi after the neurotomy. According to the authors, this study provides electrophysiological evidence in the human lumbar spine that the medial branch of the lumbar root innervates the multifidus muscle on multiple levels<sup>47</sup>. In another study in a swine, electrical stimulation of the disc annulus fibrosus induced reactions in the multifidus on multiple levels and on the contralateral side, whereas stimulation of the facet joint capsule induced reactions predominantly on the same side as and at the segmental level of the stimulation. Introduction of lidocaine into the facet joint resulted in significantly reduced electromyographic response to either stimulation, with the most drastic

reduction seen when stimulating the facet joint capsule. The clinical implications observed by the authors are that there may be interactive responses between injured or diseased structures, i.e., disc or facet joints, and the paraspinal musculature<sup>48</sup>. Dreyfuss et al<sup>49</sup> determined the effectiveness of lumbar medial branch neurotomy by performing electromyography of the multifidus muscle before and after the procedure to ensure accuracy of the neurotomy. Relief was associated with denervation of the multifidus in those segments in which the medial branches had been coagulated. The clinical implication of these studies is that EMG guidance during a medial branch block or neurotomy - whether performed with fluoroscopic guidance or by utilizing anatomical landmarks - is the only objective method of confirming accuracy of the procedure. In some patients, the paraspinal muscles may be a major contributor to the pain<sup>57 50 51 52</sup>. In such situations, the medial branch innervation of the paraspinal muscles may play an equal or more significant role than the medial branch innervation of the facet joints<sup>85 86</sup>

## PROCEDURE TECHNIQUES – WITH AND WITHOUT FLUOROSCOPY

We will now review techniques for three procedures performed with and without fluoroscopic guidance namely: Intra-capsular facet joint injection, Facet (medial branch) nerve injection and Epidural Interlaminar Injection

### INTRA-CAPSULAR FACET JOINT INJECTION

#### WITH FLUOROSCOPY

The standard technique described for a fluoroscopic guided intra-capsular facet joint injection is to puncture the skin directly over the target, align the spinal needle along the axis of the X-ray beam and direct the needle into the capsule of the facet joint. A trace amount of contrast is injected to confirm needle placement and 1 mL of local anesthetic with or without steroid is injected into the joint<sup>17</sup>. Due to the size of the facet joint fluoroscopic guidance is the only way to inject into the joint.

#### WITHOUT FLUOROSCOPY

This procedure cannot be performed without fluoroscopy.

#### FACET MEDIAL BRANCH NERVE BLOCK

##### WITH FLUOROSCOPY

The standard technique described for a fluoroscopic guided facet nerve block is the placement of a spinal needle on the superior and medial point at which the transverse process joins the vertebra. The medial branch is targeted at the point at which the nerve curves around the top of the transverse process. As described by Waldman, after correct needle placement is confirmed by fluoroscopy, 1.5 mL of local anesthetic with or without steroid is injected through the spinal needle.

##### WITHOUT FLUOROSCOPY

Several techniques for performing facet nerve blocks using anatomical landmarks have also been described<sup>17 53</sup>. As described by Raj<sup>54</sup>, the patient is placed in a

prone position and then rotated obliquely with a 30° angle pillow placed under the iliac crest of the side to be injected. For lumbar procedures, the needle is placed 6-8 cm lateral to the midpoint of the spinous process. After sterile prep and drape, a 22G to 25G, 2 inch-3 ½ inch spinal needle is advanced until bone is contacted. Gentle aspiration of the needle is carried out. If the aspiration test is negative, 2-5 mL of local anesthetic and steroid solution is injected through the spinal needle.

As described by Hoerster et al <sup>44</sup>, a larger volume of local anesthetic administered at the lamina of the vertebral arch will spread along the muscles of the frontal plane, cranially, caudally and laterally, blocking the deep areas supplied by the medial and lateral branches of the dorsal rami of the spinal nerves, including the adjacent component of the vertebral joints up to the region of the ventral rami of the spinal nerves. For a lumbar procedure, the patient is placed in a prone position. One and one-half centimeters lateral of the midline and at the level of the upper spinous process, a 4-6 cm spinal needle is introduced through a skin wheal, in a strictly sagittal plane and at 90 degrees to the skin surface. After bony contact, which may occur at a depth of 2-5 cm, depending on the thickness of the muscle layer, and after negative aspiration in two planes, a test dose of 2 mls of the local anesthetic is injected. If there is no sensation of warmth and no segmental hypesthesia, an additional 3-5 mls of local anesthetic solution is injected. Low concentrations of local anesthetic should be used.

#### EPIDURAL INTERLAMINAR INJECTION WITH FLUOROSCOPY

For a dorsal interlaminar approach, the patient is placed in the prone position.

Under fluoroscopic guidance, a 22-gauge spinal needle is advanced to the posterior margin of the spinal canal. Positioning in the epidural space is detected with a loss-of-resistance technique. Gentle intermittent pressure is applied on a syringe while advancing the needle. A sudden loss of resistance occurs on entering the epidural space. Absence of cerebrospinal fluid flow is verified with aspiration. Epidurography is performed with 2–3 mL of nonionic myelography-approved iodinated contrast material to document epidural position and evaluate the distribution pattern. Local anesthetic with steroid is then injected into the epidural space.

#### EPIDURAL INTERLAMINAR INJECTION WITHOUT FLUOROSCOPY

Using a strict aseptic technique local infiltration into the skin and interspinous ligament is performed with a small volume of local anesthetic, such as 1% lidocaine. A 16, 17, or 18 gauge Tuohy needle is then advanced into the interspinous ligament and a "loss of resistance" technique is used to identify the epidural space. Air or saline may be used for identifying the epidural space, depending on personal preference. After placement of the tip of the Tuohy needle into the epidural space, local anesthetic with steroid is injected into the epidural space. If desired, a catheter is threaded through the needle. The needle is then removed. Generally the catheter is then withdrawn slightly so that 4-6 cm remains in the epidural space.

## **ANALYSIS OF THE EVIDENCE**

### **DIAGNOSTIC BLOCK OF THE FACET JOINT CAPSULE**

The intracapsular facet joint block is achieved by injecting the local anesthetic strictly within the facet joint capsule. Due to the small size of the facet joint capsule, fluoroscopy is a requirement for this procedure. However we have not found any anatomical, mechanical or patho-physiological evidence for the targeting of the joint capsule. The joint capsule is but one component within a zone of inflammation comprising any combination of the facet joint, facet capsular ligament, spinous ligaments, spinous process, vertebral end plate, intervertebral disc and paraspinal muscle. It is an anatomical rule that joints are surrounded and stabilized by ligaments and muscles. Any trauma sufficient to injure the facet capsule will result in injury to the surrounding ligaments. The resultant inflammation will result in a nociceptive afferent and efferent output of the nerves innervating the facet joint leading to pain and spasm of the paraspinal muscles. One study compared fluoroscopically guided intra-articular and peri-articular cervical facet joint injections. There was no significant difference in response between patients receiving intra-articular or peri-articular injections<sup>55</sup> Other studies including a randomized controlled trial of facet joint injections and medial branch blocks in eighty-six patients with refractory chronic low back pain found both procedures to be of equal value<sup>56 57</sup>. In a series of 14 patients with cervicogenic headache, blockade of C2 cervical nerves resulted in freedom from pain in 5 of 10 patients compared with two patients out of 9 who reported freedom from pain following C2/C3 facet joint injection. The study authors stated that when evaluating the

C2/C3 facet joint injection, the possible leakage of anesthetic agent from the joint needs to be taken into consideration, since the third occipital nerve which runs close to the facet joint may be anesthetized through the leakage<sup>58</sup>. Another study questioned the specificity of the intraarticular facet block as a diagnostic test for facet joint disease. The study found that facet capsular rupture with epidural and periarticular diffusion is probably responsible for many false positive findings. The authors found a comparatively low success rate of the procedure in patients in whom maximal volumes were strictly controlled to avoid extravasation<sup>59</sup>. The capacity of a lumbar facet joint is 1.0-1.5 mls and a cervical facet joint is 0.5-1.0 ml. However, the anterior facet capsular ligament is often fenestrated or partially degenerated. Anterior rupture of the facet joint during injection can occur with as little as 0.2 ml of injectate and can cause anesthetization of the medial branch nerve and its peripheral branches, sinuvertebral nerves, spinal nerve, dorsal root ganglion as well as spillage of local anesthetic into the epidural space and complete loss of selectivity. One study determined the prevalence of facet joint pain in patients with chronic spine pain using controlled comparative local anesthetic blocks (1% lidocaine or 1% lidocaine followed by 0.25% bupivacaine). False-positive rates after the facet joint diagnostic blocks were 63%, 55%, and 27% for cervical, thoracic, and lumbar facet joint blocks, respectively. The authors also acknowledged that their study of chronic spine pain may be criticized because they failed to evaluate other potential sources of pain<sup>60</sup>. In addition to these significant false-positive rates and study design flaws, a placebo-controlled, double-blind evaluation has shown that even the admin-

istration of sedation with midazolam or fentanyl could be a confounding factor in the diagnosis of facet joint pain<sup>61</sup>. We have found no evidence to support the concept that a diagnostic test can be performed by an intracapsular facet joint block. We have also found no evidence to support the concept that injecting a volume of local anesthetic over the facet medial branch nerve can perform a diagnostic test and localize pain to the facet joint. The medial branch nerve innervates several structures including the facet joints, facet capsular ligaments, the interspinous and supraspinous ligaments, spinous process and paraspinal muscles. Thus relief of pain subsequent to blockade of the medial branch can be due to blockade of nociceptive afferent input from any combination of these spinal structures and/or blockade of nociceptive efferent input to the paraspinal musculature.

#### DIAGNOSTIC BLOCK OF THE MEDIAL BRANCH NERVE

Dreyfus et al performed a study to determine whether blocks of the medial branches anesthetize these nerves exclusively or whether they anesthetize other structures that are potential sources of pain. In the cadaveric study, the branches of the dorsal rami were exposed, spinal needles were placed over the nerves, and plain radiographs were taken to demonstrate the precise radiographic locations of the nerves. In the second phase of the study, healthy volunteers underwent injections of radiographic contrast over the nerves, and plain radiographs and computed tomographic images were taken. Injections were performed using different rates of injection and in two positions for each nerve.

Radiographic contrast incorporated the medial branches of the dorsal rami in every injection. However with some needle placements, aberrant flow of contrast medium was demonstrated with extension into the epidural space or intervertebral foramina. On the basis of this anatomical study Dreyfus et al concluded that if the appropriate technique is used, medial branch blocks are target specific<sup>32</sup>. There is no basis for this conclusion in the absence of any electro-diagnostic quantification of medial branch neural blockade on the adjacent spinal structures. Furthermore current techniques for fluoroscopic medial branch blocks describe three times the volume of local anesthetic (1.5 mls) that was used in the anatomical study by Dreyfus et al<sup>62</sup>. Another study by Barnsley and Bogduk determined the specificity of cervical medial branch blocks for the diagnosis of cervical zygapophyseal joint pain by ascertaining the disposition of the local anesthetic after injection of the medial branches of the cervical dorsal rami. Sixteen consecutive patients with chronic neck pain from motor vehicle accidents underwent cervical medial branch blocks. A 22-gauge, 90-mm spinal needle was placed onto the target nerve under image-intensifier guidance. Immediately after each target nerve had been infiltrated with 0.5 ml of local anesthetic, 0.5 ml of contrast medium was injected to map the spread of injectate. Radiographs were recorded to document the pattern of spread. Twenty-five injections of local anesthetic and contrast medium were performed. The authors observed that contrast medium dispersed in characteristic patterns at all vertebral levels and always incorporated at least 5 mm of the perceived course of the target nerve (sic). According to the authors, there was never any

spread to the ventral ramus, beyond the medial fibers of semispinalis capitis or to the adjacent medial branches. No other single structure was consistently within the field of the contrast. Eleven patients obtained complete or definite relief of their pain, which according to the authors could only be attributed to anesthetization of the zygapophyseal joint innervated by the nerves blocked. The authors concluded that local anesthetic blocks of the cervical medial branches are a specific test for the diagnosis of cervical zygapophyseal joint pain. The authors further stated that local anesthetic always reaches the target nerve and does not affect any other diagnostically important structures<sup>63</sup>. There is no basis for such a conclusion to be derived from visual observations of the dispersal of contrast medium to “at least 5 mm of a perceived course of a target nerve”. The medial branch nerve cannot be visualized under fluoroscopy but the study came to a conclusion based upon spread of contrast medium to a segment of its perceived course! An even more serious omission is that the study came to a conclusion that relief of their pain could only be attributed to anesthetization of the zygapophyseal joint innervated by the nerves blocked yet the authors did not conduct any electro diagnostic measurements of medial branch neural blockade of any of the other posterior spinal structures.

## INFLAMMATION AND MULTIPLE PAIN GENERATORS

The idea of localizing the pain generator to the facet joint is not sustained by any knowledge of pathophysiology. Inflammation results from a physical, chemical or biological trauma or irritation. A primary characteristic of inflammation and the

inflammatory process is recruitment and spread<sup>64</sup>. A single or cumulative traumatic or degenerative event results in spread of inflammation and multiple pain generators. In one study, a piece of gelatin sponge containing complete adjuvant was inserted into the L5-L6 facet joint in rats (arthritis group). Saline was used in the control group. Inflammatory cells infiltrating the epidural space were counted, and changes in cartilage were assessed histologically. Tumor necrosis factor (TNF)-alpha-immunoreactive cells in the L5 dorsal root ganglion were counted. Mechanical allodynia was observed in the arthritis group from day 3, gradually recovering during the observation period. Significantly larger numbers of inflammatory cells had infiltrated the epidural space by days 3 and 7 in the arthritis group than in controls. Numbers of TNF-alpha-immunoreactive cells were significantly increased at days 1 and 3 in the arthritis group compared with controls. Thus when inflammation was induced in facet joint, inflammatory reactions spread to nerve roots, and leg symptoms were induced by chemical factors<sup>40</sup>. In another study, lumbar facet joint cartilage and synovial tissues in 40 cases of posterior lumbar surgery were harvested to measure tumor necrotizing factor-alpha (TNFalpha), interleukin-1beta (IL-1beta), and interleukin-6 (IL-6) during operation. Inflammatory cytokines were detected in the joint tissues in the lumbar spinal canal stenosis (LSCS) and lumbar disc herniation (LDH) groups. Intraspinous canal tissues including lumbar nerve root were stained by injection of methylene blue into the facet joints<sup>39</sup>. Inflammatory mediators and cytokines produced by tissue injury, infection or inflammation of a spinal structure will diffuse and inflame adjacent tissues. The other immune cells, which include

white blood cells such as T helper cells, lymphocytes, neutrophils, eosinophils, and other cells such as fibroblasts and endothelial cells invade an area of injury. These immune cells respond to the chemical mediators, release destructive enzymes to kill any invading organism and release more chemical mediators to attract more immune cells. A consequence of this immune response is tissue damage, pain and muscle spasm. In a sense the initial immune reaction ignites a cascade of immune reactions and generates an inflammatory soup of chemical mediators. These chemical mediators produced by the immune cells include prostaglandin, nitric oxide, tumor necrosis factor alpha, interleukin 1-alpha, interleukin 1-beta, interleukin-4, Interleukin-6 and interleukin-8, histamine and serotonin. In the area of injury and subsequently in the spinal cord, enzymes such as cyclooxygenase increase the production of these inflammatory mediators<sup>65 66 67</sup>. There are multiple pain generators involved in inflammation of a spinal segment and the objective should be to block multiple sites of inflammation utilizing local anesthetics in combination with anti-inflammatory medication including inflammatory mediator blockers. The medial branch nerve itself may be the pain generator. Repeated firing of sensory nerves causes release of the inflammatory neuropeptides at the peripheral endings of these fibers<sup>68 69 70</sup>. These neuropeptides may induce vasodilation, increase vascular permeability, attract other immune cells such as T helper cells and excite surrounding sensory nerve fibers - the phenomenon referred to as neurogenic inflammation. At the level of the central nervous system, the increased input from peripheral pain receptors alters the central processing mechanisms and

subsequently up regulates the expression of genes associated with immune response and microglia activation in the dorsal root ganglion or spinal cord (central sensitization)<sup>71 72 64</sup>. The false positive results obtained with capsular rupture with epidural and periarticular diffusion of local anesthetics<sup>59</sup> are indicative of pain relief resulting from blockade of medial branch innervation to adjacent sites of inflammation. In one study, the duration of pain relief was significantly superior with medial branch nerve blocks utilizing local anesthetic and steroid (Depo-medrol) compared with blocks utilizing local anesthetic only<sup>73</sup>.

#### BENEFIT OF EPIDUROGRAPHY

It has been stated that the benefit of using fluoroscopy in epidural steroid injections is to perform a pre-injection epidurogram to assess whether the volume of injectate can cover the targeted nerve levels. Such statements make a presumption of the anatomical location of the source of inflammation and make a presumption that local anesthetics and steroid will exert their therapeutic effect only if injected at an exact anatomical location. There is no evidence to support these statements. One study tested the postulate that the lack of positive effects of epidural steroids in patients with radicular leg pain may in part be incorrect placement of injectate. This was in response to studies that claimed a therapeutic advantage for epiduroscopy compared with traditional epidural steroid administration techniques due to a targeted placement of corticosteroid around the affected nerve root when epiduroscopy was utilized. The study investigated whether the site of steroid placement within the epidural space made a difference

in outcome. The study randomized 60 patients with a 6–18 months history of sciatica to either targeted epidural local anesthetic and steroid placement with a spinal endoscope or caudal epidural local anesthetic and steroid treatment. Pre-treatment and 6-week, 3-month, and 6-month SF-MPQ and HAD scores were recorded. The authors concluded that the targeted placement of epidural steroid onto the affected nerve root causing sciatica does not significantly reduce pain intensity and anxiety and depression compared with untargeted caudal epidural steroid injection. When analyzed individually, both techniques benefited patients<sup>74</sup>. Another study utilized epidurography to confirm epidural filling defects for contrast dye in the patients with epidural fibrosis. Epidural adhesiolysis was performed by insertion of an epidural catheter via the sacral hiatus. Injections of contrast dye, local anesthetic, corticosteroid, and hypertonic NaCl 10% were carried out daily for 3 days. Spread of the contrast dye in the epidural space was evaluated after 10 and 20 ml injection volume. Statistical analysis (chi square analysis) could not demonstrate that improvement of contrast spread was correlated with better pain behavior<sup>75</sup>.

## INFLAMMATION AND MULTIPLE PAIN GENERATORS

Inflammation results from a physical, chemical or biological trauma or irritation. A single or cumulative traumatic or degenerative event results in spread of inflammation and multiple pain generators. In one study, lumbar facet joint cartilage and synovial tissues in 40 cases of posterior lumbar surgery were harvested to measure tumor necrotizing factor-alpha (TNFalpha), interleukin-

1beta (IL-1beta), and interleukin-6 (IL-6) during operation. Inflammatory cytokines were detected in the joint tissues in the lumbar spinal canal stenosis (LSCS) and lumbar disc herniation (LDH) groups. Intraspinous canal tissues including lumbar nerve root were stained by injection of methylene blue into the facet joints<sup>39</sup>. Inflammatory mediators and cytokines produced by tissue injury, infection or inflammation of a spinal structure will diffuse and inflame adjacent tissues. The other immune cells, which include white blood cells such as T helper cells, lymphocytes, neutrophils, eosinophils, and other cells such as fibroblasts and endothelial cells invade an area of injury. These immune cells respond to the chemical mediators, release destructive enzymes to kill any invading organism and release more chemical mediators to attract more immune cells. A consequence of this immune response is tissue damage, pain and muscle spasm. In a sense the initial immune reaction ignites a cascade of immune reactions and generates an inflammatory soup of chemical mediators. These chemical mediators produced by the immune cells include prostaglandin, nitric oxide, tumor necrosis factor alpha, interleukin 1-alpha, interleukin 1-beta, interleukin-4, Interleukin-6 and interleukin-8, [histamine](#) and [serotonin](#). In the area of injury and subsequently in the spinal cord, enzymes such as cyclooxygenase increase the production of these inflammatory mediators<sup>76 77 78</sup>. There are multiple pain generators involved in inflammation of a spinal segment and the objective should be to block multiple sites of inflammation utilizing local anesthetics in combination with anti-inflammatory medication including inflammatory mediator blockers. The medial branch nerve itself may be the pain

generator. Repeated firing of sensory nerves causes release of the inflammatory neuropeptides at the peripheral endings of these fibers<sup>79 80 81</sup>. These neuropeptides may induce vasodilation, increase vascular permeability, attract other immune cells such as T helper cells and excite surrounding sensory nerve fibers - the phenomenon referred to as neurogenic inflammation. At the level of the central nervous system, the increased input from peripheral pain receptors alters the central processing mechanisms and subsequently up regulates the expression of genes associated with immune response and microglia activation in the dorsal root ganglion or spinal cord (central sensitization)<sup>82 83 64</sup>. The false positive results obtained with capsular rupture with epidural and periarticular diffusion of local anesthetics<sup>59</sup> are indicative of pain relief resulting from blockade of medial branch innervation to adjacent sites of inflammation. In one study, the duration of pain relief was significantly superior with medial branch nerve blocks utilizing local anesthetic and steroid (Depo-medrol) compared with blocks utilizing local anesthetic only<sup>84</sup>.

#### BLOCK OF THE MEDIAL BRANCH NERVE UTILIZING ANATOMICAL LANDMARKS

Several techniques for performing therapeutic facet nerve blocks using anatomical landmarks have been described<sup>17 85 86</sup>. As described by Hoerster et al<sup>44</sup>, a larger volume of local anesthetic administered at the lamina of the vertebral arch will spread along the muscles of the frontal plane, cranially, caudally and laterally, blocking the deep areas supplied by the medial and lateral branches of the dorsal rami of the spinal nerves, including the adjacent component of the vertebral joints up to the region of the ventral rami

of the spinal nerves. There are no studies that have compared the safety, efficacy and outcome of medial branch blocks guided by fluoroscopy or guided by anatomical landmarks. However, clinicians perform thousands of epidural injections, joint, nerve blocks and regional anesthetic procedures safely and effectively every day without fluoroscopy and often on women in labor. A study of spinal anatomy will reveal that the facet medial branch nerve block has a lower risk profile than many other spinal procedures and regional anesthetic blocks that are performed utilizing anatomical landmarks. Success of the technique will occur if the anesthetic blocks the medial or lateral branch nerves that are involved in the inflammatory process or blocks the medial branch innervation to the facet joint or posterior spinal structures that are inflamed. Performance of medial branch blocks utilizing anatomical landmarks require the same training, skills and caution as for other spinal or paravertebral nerve blocks in order to avoid complications such as nerve injury and inadvertent epidural or spinal anesthesia. It should be noted that there is a greater risk of spinal cord injury from epidural blocks wherein the tip of the needle is 10-16 mm away from the spinal cord. Procedures utilizing anatomical landmarks should not be performed where such landmarks cannot be identified as in obese patients or where there is a narrow margin of safety as in the elderly. Safety of blocks utilizing anatomical landmarks is enhanced by aspiration before injection, and use of low concentration, preservative-free local anesthetic solutions.

#### NEEDLE POSITION AND SUCCESS OF A NERVE BLOCK

It has been stated by advocates of fluoroscopy that fluoroscopic verification of needle position gives inconsistent results when the facet medial branch nerve is

blocked or the epidural space is injected using anatomical landmarks (“blind technique”)<sup>14</sup>. Nerve blocks are often performed utilizing local anesthetics and steroid. Inconsistent needle position does not correlate with the success of a block or relief of pain and is not unique to a medial branch block. It is a characteristic of the simplest joint injection procedures. Intra-articular knee and shoulder joint procedures are some of the commonest procedures performed by primary care physicians and specialists. A study by Jackson and Evans in the Journal of Bone and Joint Surgery determined the accuracy of needle placement in the intra-articular space of the knee, by orthopedic surgeons performing intra-articular knee injections. Out of eighty injections performed through an anterolateral portal, fifty-seven were confirmed to have been placed in the intra-articular space on the first attempt (an accuracy rate of 71%)<sup>87</sup>.

Needle position does not predict the success of a nerve block. The success rate of a nerve block or joint injection with or without fluoroscopy is higher than is predicted by accuracy of needle placement because of the diffusion and perineural transport of the local anesthetic and steroid. One study characterized the local anesthetic spread of injectate resulting from a single-injection technique of deep cervical plexus block. The authors showed that the spread of injectate had a large volume exceeding twice that of the injectate<sup>88</sup>. Studies have been published that have utilized fluoroscopy to verify needle placement and success of the regional anesthetic or epidural procedure utilizing anatomical landmarks. Fredman et al examined the effect of fluoroscopy on improving the accuracy and possible efficacy of an epidural steroid injection. In the study, the epidural steroid

reached the anatomical level of pathology only 26% of the time despite fluoroscopic guidance<sup>89</sup>. However the effect of the steroid extends beyond the anatomical level visualized under fluoroscopy. Renfrew found that 14.2% of caudal epidurals and 34% of interlaminar epidurals placed by experienced physicians using anatomical landmarks are found to be misplaced when verified by fluoroscopy<sup>90</sup>. These figures are often quoted in the pain and radiology literature, and one article stated that even in experienced hands, blind epidural steroid injections result in inaccurate needle placement in up to 30% of cases<sup>91</sup>. Another article stated that epidural injection of steroid and local anesthesia used to treat low back pain is best performed with fluoroscopic control, with needle placement documented by means of a limited epidurogram<sup>16</sup>. None of these articles provide any documentation of the success or failure rate of the epidural injection. In fact, a study in the journal Reg Anesth Pain Med showed a 95% success rate of labor epidurals placed using anatomical landmarks that were reactivated at a later time for postpartum tubal ligation<sup>92 93</sup>. Several studies have verified the success of nerve or epidural blocks utilizing anatomical landmarks. In one study of caudal epidural injections, fluoroscopy revealed incorrect placement by staff physicians confident of their anatomical landmarks 14.2% of the time (seven of 49 procedures)<sup>90</sup>. In addition, when the needle was positioned within the sacral canal and no blood was evident on Valsalva maneuver or aspiration, the injection was venous in 29 of 316 procedures performed by both staff physicians and residents (9.2%). In another study, the combination of two anatomical landmark signs predicted a successful caudal epidural injection in

91.3% of attempts<sup>94</sup>. In yet another study, radiological studies confirmed the clinical impression that the epidural space had been successfully identified using anatomical landmarks in 91.6% of the time. The authors stated that because of ever-increasing medical expenditures, the cost-benefit of routine fluoroscopy should be critically evaluated<sup>89</sup>. One study examined the site of catheter tips and the spread of contrast material in the epidural space using computed tomographic (CT) imaging in patients receiving successful epidural analgesia. Catheter tips were most often found lateral to the dura in the intervertebral foramen. In these subjects with normally functioning epidural analgesia, there was remarkable inter-individual variability in patterns of spread, including various amounts of anterior passage, layering along the dura, and compression of the dura creating a posterior fold. The author concluded that non-uniform distribution of injectate is common and is compatible with uniform anesthesia<sup>95</sup>. Success of a nerve block requires a needle to be within the vicinity of a nerve and not exactly on the nerve.

## **CONCLUSION**

There is no physiological or biomechanical evidence for a single pain trigger in the spine where inflammation is confined. Inflammation and the inflammatory process are characterized by recruitment and spread. There is evidence to revise the current focus on searching for one pain trigger at a time to acknowledging the existence of and targeting multiple pain triggers responsible for spinal pain. There is evidence for the therapeutic utility of blockade of the

medial branch nerve innervation of the posterior spinal structures that are involved in inflammation and pain. There is a need for more research and clinical trials to improve the current structural pathology based diagnosis and treatment of spinal pain to biochemical imaging and interventions that address the role of cytokine and inflammatory mediators, neuroplasticity and central/peripheral sensitization in the biochemical pathology of spinal pain. In the hands of a skilled physician, a facet medial branch nerve block or epidural injection is similar to other spinal nerve block procedures. These procedures can be performed safely and effectively with or without fluoroscopy. There is no evidence to support a requirement for the use of fluoroscopy to perform facet medial branch nerve blocks or epidural injections. Use of fluoroscopy for facet medial branch nerve blocks and epidural injections should be optional and depend on the skill, training and comfort of the individual clinician and a cost-benefit analysis.

Fluoroscopy should be utilized when anatomical landmarks are unreliable or difficult to discern and in the performance of procedures that bring the needle close to vital structures such as a celiac plexus block or with nerve destruction procedures such as radiofrequency lesioning.

We have found no evidence to support the performance of intra-capsular facet joint injections for either diagnosis or treatment. As a diagnostic tool, the facet intra-capsular injection is meaningless and this procedure should be discontinued. There is no evidence that fluoroscopic guidance can result in a controlled or limited block of the medial branch innervation to the facet joint. A

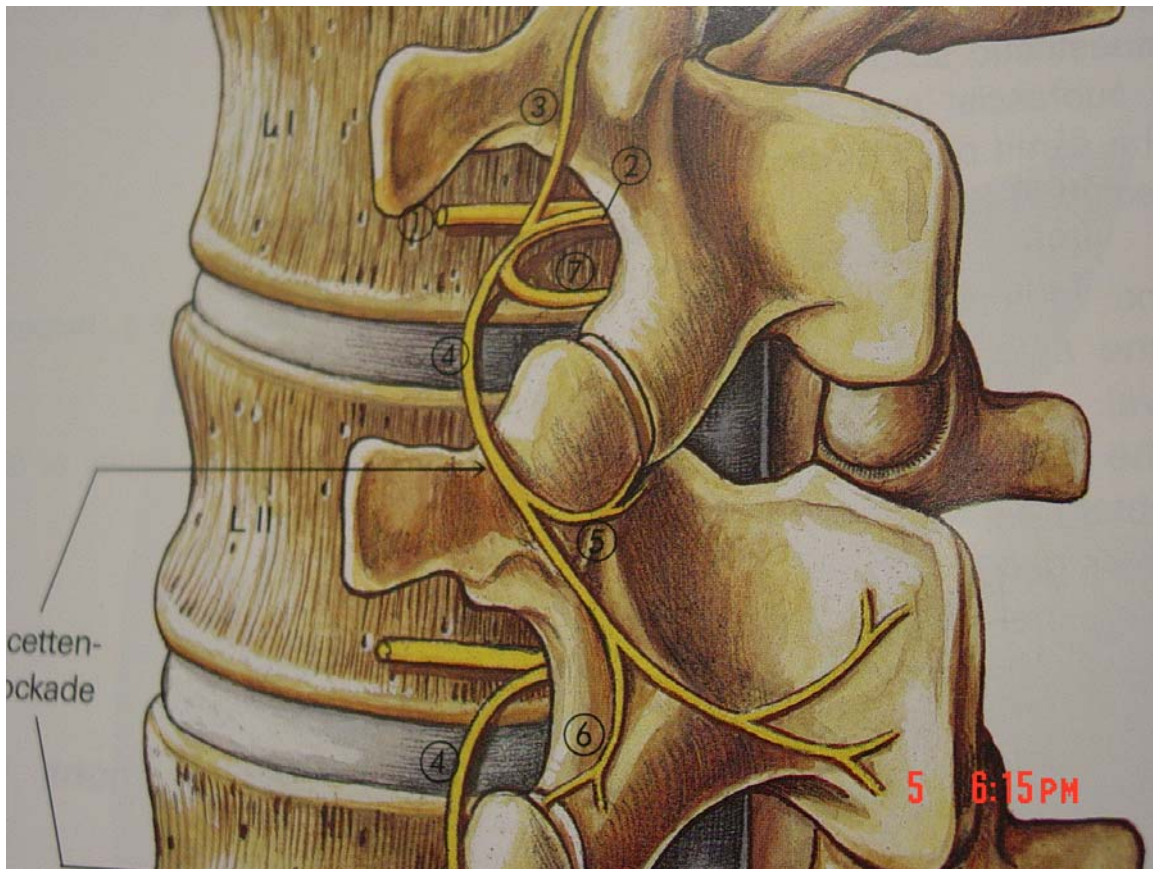
medial branch block administered as a diagnostic test cannot localize the pain to the facet joint. In the absence of systemic analgesia, the block localizes the pain to any or several of the posterior spinal structures innervated by the medial branch nerve. Lack of diagnostic localization to the facet joint does not affect the therapeutic utility of medial branch blocks, as inflammation subsequent to injury is not confined to a single posterior spinal structure. There is evidence for the therapeutic utility of a blockade of the medial branch nerve and the posterior spinal structures that are involved in inflammation and pain. Fluoroscopy enables better structural accuracy of needle positioning over a bony landmark, but structural accuracy may not correlate with efficacy or outcome of neural blockade or pain relief. Structural accuracy enables blockade of the nerve branches in close proximity. However, the nerve branches being blocked may or may not innervate the posterior spinal structures that are involved in inflammation and pain. There is no evidence that a block utilizing fluoroscopy translates into a greater therapeutic advantage than a block performed utilizing anatomical landmarks. Techniques of medial branch blockade utilizing fluoroscopy or anatomical landmarks are both biochemically and electro-diagnostically blind. Neither technique can visualize or target the branches of the medial branch nerve that are involved in the inflammatory process. EMG guidance during a medial branch block - whether performed with fluoroscopic guidance or by utilizing anatomical landmarks - is the only objective method of confirming accuracy of the procedure. Technologies such as MRI spectroscopy that can image inflammation are currently experimental. There is no evidence of any

studies that demonstrate increased safety, efficacy or outcome of facet medial branch nerve blocks or epidural injections using fluoroscopy compared with the use of anatomical landmarks. However it should be noted that the absence of proof for medial branch blocks, i.e. the fact that there are no controlled studies comparing blocks with and without imaging, does not necessarily mean that the success rate is not different.

The increased use of fluoroscopy should translate into a better safety record and decrease the frequency and payments of claims associated with chronic pain management procedures but the opposite has occurred. Research is required to determine if this increase in chronic pain claims reflects a change in liability or an increase in the number of procedures performed. Research should determine the correlation of claims to the level of training and experience of those performing these procedures. Safety dividends that should accrue from the use of fluoroscopy may be offset by complacency due to a false sense of security, increased risk of spinal cord injury with the prone position required in fluoroscopic epidurals and increased performance of procedures with a greater risk of nerve or spinal cord injury, yet unproven and questionable therapeutic advantage, such as transforaminal epidurals. More cost-benefit and risk-benefit analysis of some of these procedures are required. The constant questioning of “established” truths is necessary for progress in the specialty of pain medicine and improvement in outcome at optimum cost.

Figure 1 – Anatomy of the Facet Medial Branch Nerve<sup>44</sup>

1. Ventral branch of the dorsal ramus
2. Dorsal ramus of spinal nerve
3. Ascending branch of spinal nerve
4. Medial branch of dorsal ramus
5. Inferior articular branch of medial branch
6. Superior articular branch of medial branch
7. Sinuvertebral nerve of Luschka



## REFERENCES

- <sup>1</sup> Benini A. [Acute lumbago. Guidelines for clinical practice] [Article in German] Schweiz Rundsch Med Prax. 1990 Mar 6;79(10):280-3.
- <sup>2</sup> Fukuyama S, Nakamura T, Ikeda T, Takagi K. The effect of mechanical stress on hypertrophy of the lumbar ligamentum flavum. J Spinal Disord. 1995 Apr;8(2):126-30
- <sup>3</sup> Butler D, Trafimow JH, Andersson GB, McNeill TW, Huckman MS. Discs degenerate before facets. Spine. 1990 Feb;15(2):111-3.
- <sup>4</sup> Scutellari PN, Rizzati R, Antinolfi G, Malfaccini F, Leprotti S, Campanati P. The value of computed tomography in the diagnosis of low back pain. A review of 2,012 cases. Minerva Med. 2005 Feb;96(1):41-59
- <sup>5</sup> Paściak M, Besler K, Doniec J, Smigiel M. The effect of joint facet asymmetry on the pathogenesis of lower segments of the lumbar spine. [Article in Polish] Chir Narzadow Ruchu Ortop Pol. 1997;62(3):219-23
- <sup>6</sup> Swezey RL  
Low back pain in the elderly: practical management concerns. Geriatrics. 1988 Feb;43(2):39-44
- <sup>7</sup> Jensen MC, Brant-Zawadzki MN, Obuchowski N, Modic MT, Malkasian D, Ross JS.. Magnetic resonance imaging of the lumbar spine in people without back pain. N Engl J Med 1994 Jul 14;331(2):69-73
- <sup>8</sup> Boos N, Semmer N, Elfering A, Schade V, Gal I, Zanetti M, Kissling R, Buchegger N, Hodler J, Main CJ. Natural history of individuals with asymptomatic disc abnormalities in magnetic resonance imaging: predictors of low back pain-related medical consultation and work incapacity. Spine. 2000 Jun 15;25(12):1484-92.
- <sup>9</sup> Straus BN. Chronic pain of spinal origin: the costs of intervention. Spine. 2002 Nov 15;27(22):2614-9
- <sup>10</sup> Pauza KJ . PASSOR Educational Guidelines for the performance of Spinal Injection Procedures. Physiatrix Association of Spine, Sports and Occupational Rehabilitation (PASSOR) - American Academy of Physical Medicine and Rehabilitation 2004
- <sup>11</sup> Manchikanti L, Singh V, Kloth, D, Slipman, CW, Jasper, JF, Trescot, AM, Varley, KG, Atluri, SL, Giron, C, Curran, MJ, Rivera, J, Baha, AG, Bakhit, CE, Reuter, MW  
ASIPP Practice Guidelines : Interventional Techniques in the Management of Chronic Pain: Part 2.0 2001, American Society of Interventional Pain Physicians  
Pain Physician, Volume 4, Number 1, pp 24-98

<sup>12</sup> Silbergleit R, Mehta BA, Sanders WP, Talati SJ. Imaging-guided injection techniques with fluoroscopy and CT for spinal pain management. Radiographics. 2001 Jul-Aug;21(4):927-39; discussion 940-2.

<sup>13</sup> Ben Hamouda M, Berguaoui N, Ben Amor H, Zouari S, Ladab MF. [Radiologically guided lumbar injections] [Article in French] Tunis Med. 2002 Jul;80(7):365-9.

<sup>14</sup> Mironer, Y. Eugene and Judson J. Somerville. Letter to editor criticizing article on blind facet joint injection, Pain Digest, 8:4:273-274, 1998

<sup>15</sup> Carrera GF. Lumbar facet joint injection in low back pain and sciatica: description of technique. Radiology. 1980 Dec;137(3):661-4.

<sup>16</sup> el-Khoury GY, Ehara S, Weinstein JN, Montgomery WJ, Kathol MH. Epidural steroid injection: a procedure ideally performed with fluoroscopic control. Radiology. 1988 Aug;168(2):554-7.

<sup>17</sup> Waldman SD Tutorial 33: The Current Status of Lumbar Facet Block Utilizing the Medial Branch Approach in the Contemporary Practice of Pain Management Pain Digest. 1998;8:41-46

<sup>18</sup> Saunders S Cameron G. Longworth S. Injection Techniques in Orthopedic and Sports Medicine 2<sup>nd</sup> Ed 1997 pp 128-129 Baillière Tindall 2002

<sup>19</sup> Raj PP (ed) Pain Medicine - A comprehensive Review pp 268-269. Mosby Inc. 1995

<sup>20</sup> Houten JK, Errico TJ. Paraplegia after lumbosacral nerve root block: report of three cases. Spine J. 2002 Jan-Feb;2(1):70-5.

<sup>21</sup> McLain RF, Fry M, Hecht ST. Transient paralysis associated with epidural steroid injection. J Spinal Disord. 1997 Oct;10(5):441-4.

<sup>22</sup> Fitzgibbon DR, Posner KL, Domino KB, Caplan RA, Lee LA, Cheney FW; American Society of Anesthesiologists. Chronic pain management: American Society of Anesthesiologists Closed Claims Project. Anesthesiology. 2004 Jan;100(1):98-105.

<sup>23</sup> Liao D.W. Trends in Chronic Pain Management Malpractice Claims .ASA Newsletter August 2007 Volume 71 Number 8

<sup>24</sup> Scanlon GC, Moeller-Bertram T, Romanowsky SM, Wallace MS. Cervical transforaminal epidural steroid injections: more dangerous than we think? Spine. 2007 May 15;32(11):1249-56.

- <sup>25</sup> [Cluff R](#), [Mehio AK](#), [Cohen SP](#), [Chang Y](#), [Sang CN](#), [Stojanovic MP](#). The technical aspects of epidural steroid injections: a national survey. [Anesth Analg](#). 2002 Aug;95(2):403-8, table of contents.
- <sup>26</sup> Kaneko T, Iwama H. The association between injected volume of local anesthetic and spread of epidural anesthesia: a hypothesis. *Reg Anesth Pain Med*. 1999 Mar-Apr;24(2):153-7.
- <sup>27</sup> Hogan Q. Epidural catheter tip position and distribution of injectate evaluated by computed tomography. *Anesthesiology*. 1999 Apr;90(4):964-70
- <sup>28</sup> Slipman CW, Bhat AL, Gilchrist RV, Issac Z, Chou L, Lenrow DA. A critical review of the evidence for the use of zygapophysial injections and radiofrequency denervation in the treatment of low back pain. *Spine J*. 2003 Jul-Aug;3(4):310-6
- <sup>29</sup> Bogduk N. Diagnostic nerve blocks in chronic pain. *Best Pract Res Clin Anaesthesiol* 2002 Dec;16(4):565-78
- <sup>30</sup> [Barnsley L](#). Percutaneous radiofrequency neurotomy for chronic neck pain: outcomes in a series of consecutive patients. [Pain Med](#). 2005 Jul-Aug;6(4):282-6.
- <sup>31</sup> Shah, RV, Kaye, AD Evolving concepts in the understanding of Cervical Facet Joint Pain. *Pain Physician*. 2004;7:295-299, ISSN 1533-3159
- <sup>32</sup> [Dreyfuss P](#), [Schwarzer AC](#), [Lau P](#), [Bogduk N](#). Specificity of lumbar medial branch and L5 dorsal ramus blocks. A computed tomography study. [Spine](#). 1997 Apr 15;22(8):895-902.
- <sup>33</sup> Sung DH. Locating the target nerve and injectate spread in rabbit sciatic nerve block. *Reg Anesth Pain Med*. 2004 May-Jun;29(3):194-200
- <sup>34</sup> Selander D, Sjostrand J. Longitudinal spread of intraneurally injected local anesthetics. An experimental study of the initial neural distribution following intraneural injections. *Acta Anaesthesiol Scand*. 1978;22(6):622-34.
- <sup>35</sup> Hildebrandt J. [Relevance of nerve blocks in treating and diagnosing low back pain--is the quality decisive?] [Article in German] [Schmerz](#). 2001 Dec;15(6):474-83
- <sup>36</sup> Hirsch C, Ingelmark BE, Miller M: The anatomical basis for low back pain. Studies on the presence of sensory nerve endings in ligamentous, capsular and intervertebral disc structures in the human lumbar spine. *Acta Orthop Scand* 1963; 33

- <sup>37</sup> Giles LG, Harvey AR: Immunohistochemical demonstration of nociceptors in the capsule and synovial folds of human zygapophyseal joints. *Br J Rheumatol* 1987 Oct; 26(5): 362-4
- <sup>38</sup> Hunter OK Cervical Sprain and Strain Emedicine 2005
- <sup>39</sup> Igarashi A, Kikuchi S, Konno S. Correlation between inflammatory cytokines released from the lumbar facet joint tissue and symptoms in degenerative lumbar spinal disorders *J Orthop Sci.* 2007 Mar;12(2):154-60. Epub 2007 Mar 30..
- <sup>40</sup> Tachihara H, Kikuchi S, Konno S, Sekiguchi M.  
Does facet joint inflammation induce radiculopathy? an investigation using a rat model of lumbar facet joint inflammation.  
*Spine.* 2007 Feb 15;32(4):406-12.
- <sup>41</sup> Bogduk N, Wilson AS, Tynan W. The human lumbar dorsal rami. *J Anat.* 1982 Mar;134(Pt 2):383-97.
- <sup>42</sup> Williams KD, Park AL. Lower Back Pain and Disorders of Intervertebral Discs. In Campbell's Operative Orthopedics, 10th Ed. Canale ST (ed.) St.Louis, Mosby, 2003; 1982-2013.
- <sup>43</sup> Maigne JY, Maigne R, Guerin-Surville H. Upper thoracic dorsal rami: anatomic study of their medial cutaneous branches. *Surg Radiol Anat.* 1991;13(2):109-12.
- <sup>44</sup> Hoerster W. et al (eds). Regional Anesthesia. St Louis, Missouri. Mosby Year Book 1990.
- <sup>45</sup> Johnson GM. The sensory and sympathetic nerve supply within the cervical spine: review of recent observations. *Man Ther.* 2004 May;9(2):71-6
- <sup>46</sup> Kang YM, Choi WS, Pickar JG. Electrophysiologic evidence for an intersegmental reflex pathway between lumbar paraspinal tissues. *Spine.* 2002 Feb 1;27(3):E56-63.
- <sup>47</sup> Wu PB, Date ES, Kingery WS. The lumbar multifidus muscle in polysegmentally innervated. *Electromyogr Clin Neurophysiol.* 2000 Dec;40(8):483-5.
- <sup>48</sup> Indahl A, Kaigle A, Reikeras O, Holm S. Electromyographic response of the porcine multifidus musculature after nerve stimulation. *Spine.* 1995 Dec 15;20(24):2652-8
- <sup>49</sup> Dreyfuss P, Halbrook B, Pauza K, Joshi A, McLarty J, Bogduk N. Efficacy and validity of radiofrequency neurotomy for chronic lumbar zygapophysial joint pain. *Spine.* 2000 May 15;25(10):1270-7

- <sup>50</sup> Haig AJ. Paraspinal denervation and the spinal degenerative cascade. *Spine J.* 2002 Sep-Oct;2(5):372-80
- <sup>51</sup> Zoidl G, Grifka J, Boluki D, Willburger RE, Zoidl C, Krämer J, Dermietzel R, Faustmann PM. Molecular evidence for local denervation of paraspinal muscles in failed-back surgery/postdiscotomy syndrome. *Clin Neuropathol.* 2003 Mar-Apr;22(2):71-7.
- <sup>52</sup> Kader DF, Wardlaw D, Smith FW. Correlation between the MRI changes in the lumbar multifidus muscles and leg pain. *Clin Radiol.* 2000 Feb;55(2):145-9.
- <sup>53</sup> Saunders S: *Injection Techniques in Orthopedic and Sports Medicine* 2<sup>nd</sup> Ed 1997 pp 128-129
- <sup>54</sup> Raj PP (ed): *Pain Medicine – A comprehensive Review.* Mosby pp 268-269
- <sup>55</sup> Roy DF, Fleury J, Fontaine SB, Dussault RG. Clinical evaluation of cervical facet joint infiltration. *Can Assoc Radiol J.* 1988 Jun;39(2):118-20.
- <sup>56</sup> Marks RC, Houston T, Thulbourne T. Facet joint injection and facet nerve block: a randomised comparison in 86 patients with chronic low back pain. *Pain.* 1992 Jun;49(3):325-8.
- <sup>57</sup> Manchikanti L. Facet Joint Pain and the Role of Neural Blockade in Its Management. *Curr Rev Pain.* 1999;3(5):348-358
- <sup>58</sup> Bovim G, Berg R, Dale LG. Cervicogenic headache: anesthetic blockades of cervical nerves (C2-C5) and facet joint (C2/C3). *Pain.* 1992 Jun;49(3):315-20.
- <sup>59</sup> Raymond J, Dumas JM. Intraarticular facet block: diagnostic test or therapeutic procedure? *Radiology.* 1984 May;151(2):333-6.
- <sup>60</sup> Manchikanti L, Boswell MV, Singh V, Pampati V, Damron KS, Beyer CD. Prevalence of facet joint pain in chronic spinal pain of cervical, thoracic, and lumbar regions. *BMC Musculoskelet Disord.* 2004 May 28;5:15.
- <sup>61</sup> Manchikanti L, Pampati V, Damron K et al. A randomized, prospective, double blind, placebo-controlled evaluation of the effect of sedation on diagnostic validity of cervical facet joint pain. *Pain Physician* 2004;7: 301-309.
- <sup>62</sup> Waldman SD, Winnie AP: *Interventional Pain Management.* Philadelphia, Saunders, 1996, p 294
- <sup>63</sup> Barnsley L, Bogduk N. Medial branch blocks are specific for the diagnosis of cervical zygapophyseal joint pain. *Reg Anesth.* 1993 Nov-Dec;18(6):343-50.

<sup>64</sup> Omoigui S The Biochemical Origin of Pain: How a new law and new drugs have led to a medical breakthrough in the treatment of Persistent pain. Hawthorne, California. State-of-the-Art Technologies Publishers 2004

<sup>65</sup> Tarek A. Samad, Kimberly A. Moore, Adam Sapirstein, Sara Billet, Andrew Allchorne, Stephen Poole, Joseph V. Bonventre & Clifford J. Woolf Interleukin-1-mediated induction of Cox-2 in the CNS contributes to inflammatory pain hypersensitivity. *Nature* 410, 471 - 475 (2001)

<sup>66</sup> Med Hypotheses. 2007 Jan 18; [Epub ahead of print]  
The biochemical origin of pain - Proposing a new law of pain: The origin of all pain is inflammation and the inflammatory response. Part 1 of 3 - A unifying law of pain. Omoigui S.

<sup>67</sup> Med Hypotheses. 2007 Aug 27; [Epub ahead of print]  
The biochemical origin of pain: The origin of all pain is inflammation and the inflammatory response. Part 2 of 3 – Inflammatory profile of pain syndromes Omoigui S.

<sup>68</sup> Ma C, Greenquist KW, Lamotte RH. Inflammatory mediators enhance the excitability of chronically compressed dorsal root ganglion neurons. *J Neurophysiol.* 2006 Apr;95(4):2098-107. Epub 2005 Dec 28.

<sup>69</sup> Hingtgen CM, Waite KJ, Vasko MR. Prostaglandins facilitate peptide release from rat sensory neurons by activating the adenosine 3',5'-cyclic monophosphate transduction cascade. *J Neurosci.* 1995 Jul;15(7 Pt 2):5411-9

<sup>70</sup> Kellstein DE, Price DD, Hayes RL, Mayer DJ. Evidence that substance P selectively modulates C-fiber-evoked discharges of dorsal horn nociceptive neurons. *Brain Res.* 1990 Sep 3;526(2):291-8

<sup>71</sup> Groth RD, Coicou LG, Mermelstein PG, Seybold VS. Neurotrophin activation of NFAT-dependent transcription contributes to the regulation of pro-nociceptive genes. *J Neurochem.* 2007 Aug;102(4):1162-74.

<sup>72</sup> Rodriguez Parkitna J, Korostynski M, Kaminska-Chowanec D, Obara I, Mika J, Przewlocka B, Przewlocki R. Comparison of gene expression profiles in neuropathic and inflammatory pain. *J Physiol Pharmacol.* 2006 Sep;57(3):401-14

<sup>73</sup> Manchikanti L, Pampati V, Fellows B, Bakhit CE. The diagnostic validity and therapeutic value of lumbar facet joint nerve blocks with or without adjuvant agents. Curr Rev Pain. 2000;4(5):337-44.

<sup>74</sup> Dashfield AK, Taylor MB, Cleaver JS, Farrow D. Comparison of caudal steroid epidural with targeted steroid placement during spinal endoscopy for chronic sciatica: a

prospective, randomized, double-blind trial. Br J Anaesth. 2005 Apr;94(4):514-9. Epub 2005 Feb 4.

<sup>75</sup> Devulder J, Bogaert L, Castille F, Moerman A, Rolly G. Relevance of epidurography and epidural adhesiolysis in chronic failed back surgery patients. Clin J Pain. 1995 Jun;11(2):147-50.

<sup>76</sup> Tarek A. Samad, Kimberly A. Moore, Adam Sapirstein, Sara Billet, Andrew Allchorne, Stephen Poole, Joseph V. Bonventre & Clifford J. Woolf Interleukin-1-mediated induction of Cox-2 in the CNS contributes to inflammatory pain hypersensitivity. Nature 410, 471 - 475 (2001)

<sup>77</sup> Med Hypotheses. 2007 Jan 18; [Epub ahead of print]  
The biochemical origin of pain - Proposing a new law of pain: The origin of all pain is inflammation and the inflammatory response. Part 1 of 3 - A unifying law of pain. Omoigui S.

<sup>78</sup> Med Hypotheses. 2007 Aug 27; [Epub ahead of print]  
The biochemical origin of pain: The origin of all pain is inflammation and the inflammatory response. Part 2 of 3 – Inflammatory profile of pain syndromes Omoigui S.

<sup>79</sup> Ma C, Greenquist KW, Lamotte RH. Inflammatory mediators enhance the excitability of chronically compressed dorsal root ganglion neurons. J Neurophysiol. 2006 Apr;95(4):2098-107. Epub 2005 Dec 28.

<sup>80</sup> Hingtgen CM, Waite KJ, Vasko MR. Prostaglandins facilitate peptide release from rat sensory neurons by activating the adenosine 3',5'-cyclic monophosphate transduction cascade. J Neurosci. 1995 Jul;15(7 Pt 2):5411-9

<sup>81</sup> Kellstein DE, Price DD, Hayes RL, Mayer DJ. Evidence that substance P selectively modulates C-fiber-evoked discharges of dorsal horn nociceptive neurons. Brain Res. 1990 Sep 3;526(2):291-8

<sup>82</sup> Groth RD, Coicou LG, Mermelstein PG, Seybold VS. Neurotrophin activation of NFAT-dependent transcription contributes to the regulation of pro-nociceptive genes. J Neurochem. 2007 Aug;102(4):1162-74.

<sup>83</sup> Rodriguez Parkitna J, Korostynski M, Kaminska-Chowaniec D, Obara I, Mika J, Przewlocka B, Przewlocki R. Comparison of gene expression profiles in neuropathic and inflammatory pain. J Physiol Pharmacol. 2006 Sep;57(3):401-14

<sup>84</sup> [Manchikanti L](#), [Pampati V](#), [Fellows B](#), [Bakhit CE](#). The diagnostic validity and therapeutic value of lumbar facet joint nerve blocks with or without adjuvant agents. [Curr Rev Pain](#). 2000;4(5):337-44.

- <sup>85</sup> Saunders S: Injection Techniques in Orthopedic and Sports Medicine 2<sup>nd</sup> Ed 1997 pp 128-129
- <sup>86</sup> Raj PP (ed): Pain Medicine – A comprehensive Review. Mosby pp 268-269
- <sup>87</sup> Jackson DW, Evans NA, Thomas BM. Accuracy of needle placement into the intra-articular space of the knee. J Bone Joint Surg Am. 2002 Sep;84-A(9):1522-7. Comment in: J Bone Joint Surg Am. 2003 Dec;85-A(12):2481; author reply 2481. J Bone Joint Surg Am. 2004 Feb;86-A(2):433-4; author reply 434.
- <sup>88</sup> Dhonneur G, Saidi NE, Merle JC, Asfazadourian H, Ndoko SK, Bloc S. Demonstration of the spread of injectate with deep cervical plexus block: a case series. Reg Anesth Pain Med. 2007 Mar-Apr;32(2):116-9.
- <sup>89</sup> Fredman B, Nun MB, Zohar E, Iraqi G, Shapiro M, Gepstein R, Jedeikin R. Epidural steroids for treating "failed back surgery syndrome": is fluoroscopy really necessary? Anesth Analg. 1999 Feb;88(2):367-72.
- <sup>90</sup> Renfrew DL, Moore TE, Kathol MH, el-Khoury GY, Lemke JH, Walker CW. Correct placement of epidural steroid injections: fluoroscopic guidance and contrast administration. AJNR Am J Neuroradiol. 1991 Sep-Oct;12(5):1003-7.
- <sup>91</sup> Johnson BA, Schellhas KP, Pollei SR. Epidurography and therapeutic epidural injections: technical considerations and experience with 5334 cases. AJNR Am J Neuroradiol. 1999 Apr;20(4):697-705.
- <sup>92</sup> Goodman EJ, Dumas SD. The rate of successful reactivation of labor epidural catheters for postpartum tubal ligation surgery. Reg Anesth Pain Med. 1998 May-Jun;23(3):258-61
- <sup>93</sup> Doughty A. Lumbar epidural analgesia--the pursuit of perfection. With special reference to midwife participation. Anaesthesia. 1975 Nov;30(6):741-51.
- <sup>94</sup> Stitz MY, Sommer HM. Accuracy of blind versus fluoroscopically guided caudal epidural injection. Spine. 1999 Jul 1;24(13):1371-6
- <sup>84</sup> Van Kleef M. (ed) Radiofrequency Lesions of the Dorsal Root Ganglion in the Treatment of Spinal Pain. Proefschrift, Maastricht 1996
- <sup>85</sup> Haig AJ. Paraspinal denervation and the spinal degenerative cascade. Spine J. 2002 Sep-Oct;2(5):372-80
- <sup>86</sup> Danneels LA, Vanderstraeten GG, Cambier DC, Witvrouw EE, De Cuyper HJ. CT imaging of trunk muscles in chronic low back pain patients and healthy control subjects. Eur Spine J. 2000 Aug;9(4):266-72

<sup>95</sup> Hogan Q. Epidural catheter tip position and distribution of injectate evaluated by computed tomography. Anesthesiology. 1999 Apr;90(4):964-70